

Anton Babinski Syndrome - A Rare Complication of Cortical Blindness

Mohammed Khalid*, Mohamed Hamdy, Himanshi Singh, Kiran Kumar, Shaikh Altaf Basha

Email: mkhalid79.med@gmail.com

Abstract

In this case report, we present a rare complication of cortical blindness, which is Anton Babinski syndrome. Patients with this syndrome usually disaffirm their blindness and confabulate to fill in missing visual information. The commonest etiology of cortical blindness is posterior cerebral artery infarction but in this particular report, we present a case of hypertensive patient with Anton Babinski syndrome who developed bilateral cerebral haematoma confined to parieto-occiput area.

Key words: Anton Babinski, Cortical Blindness, cerebral haematoma

Introduction

Cortical blindness is one of the rare neurological conditions characterized by binocular vision loss due to insult in the occipital cortex. Pupillary light reflexes are preserved, as anterior visual pathway is intact. One of the rare complications of cortical blindness is Anton Babinski Syndrome. This syndrome results from damage to visual association cortex (brodmann area 18, 19) along with primary visual cortex (brodmann area 17) [1, 2]. In this case report, we present a rare complication of cortical blindness, which is Anton Babinski syndrome.

Case Presentation

A 45-year-old man presented to an Emergency department with complains of severe headache

and blurring of vision. He was unable to walk and brought by his relative to Emergency room. He could not remember what happened during the day and was confused. No history of weakness and sensory symptoms. There was no urinary incontinence. He was known hypertensive and was on atenolol 50 mg once daily. He was not under regular follow-up with his physician. He was a barber by occupation and smokes around 3-4 cigarettes per day. No history of alcohol or drug intake.

On examination he was conscious, oriented with time, place and person but was not able to maintain eye contact. The blood pressure was 210/120 mmHg and pulse was 62/minutes and regular. He maintained that he could see our blurred faces. However, on visual field examination his visual field was markedly decreased with absence of perception of torch light. Pupils were dilated and reactive to light. Fundus examination appeared normal. No sensory or motor deficit was present and both superficial and deep reflexes were intact. Other systemic examination was unremarkable.

He was given amlodipine and perindopril to lower down the blood pressure. CT brain was done which revealed bilateral occipital fresh intracerebral haematoma (Figure 1). He was initiated on mannitol

Mohammed Khalid*

Department of Internal Medicine, GMC Hospital and Research Centre, Ajman

Kiran Kumar

Department of Internal Medicine, GMC Hospital and Research Centre, Ajman

Mohamed Hamdy

Department of Neurology, GMC Hospital and Research Centre, Ajman

Himanshi Singh

Gulf Medical University

How to cite this article: Khalid M, Hamdy M, Singh H, Kiran Kumar, Shaikh Altaf Basha. Anton Babinski Syndrome - A Rare Complication of Cortical Blindness. *MJMS* 2016; 1(1): 49-52.

and phenytoin. After neuro-surgical opinion, it was decided to manage him conservatively. On day two his headache had reduced and vision improved slightly with perception of lights and abnormal finger counting.

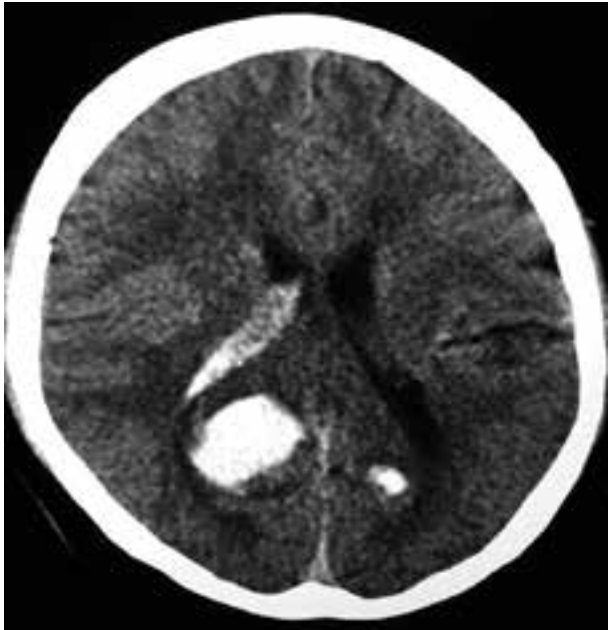

Figure 1. CT Brain showed bilateral occipital fresh intracerebral haematoma

His blood pressure was gradually reduced to 160/80 mmHg over a period of three days. MRA was done which showed right parieto-occipital and small left occipital acute to sub-acute haematoma. Multiple scattered cerebral, pontine, and cerebellar petechial haemorrhage was observed (figure 2, 3).

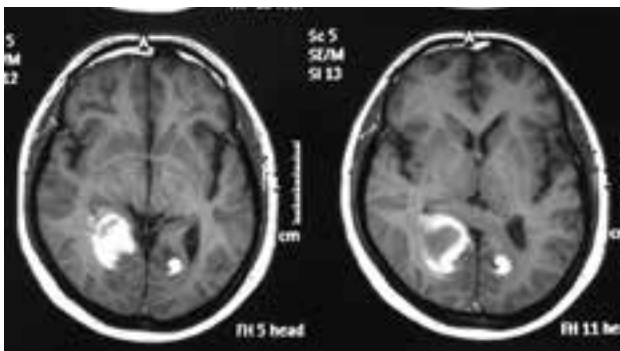


Figure 2: MRA showed right parieto-occipital and small left occipital acute to sub-acute hematoma.

He was discharged after one week of hospital stay. At the time of discharge, his visual acuity was 6/12 in both eyes. He wanted to go his home country for further treatment. The case study points towards

diagnosis of Anton syndrome where the patient denies blindness. In our case, the patient did not tell his relative about his loss of vision but explained that he can see although it is blurred.

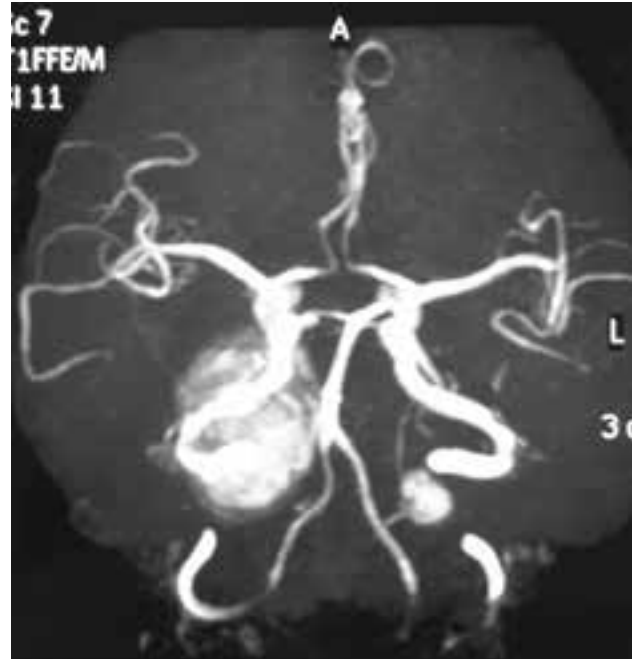

Figure 3: MRA showing no evidence of intracranial aneurysm

Discussion

Anton Babinski syndrome is a condition in which patients disaffirm their blindness (visual anosognosia) in spite of complete amaurosis of central origin (cortical blindness). In this, patients adamantly claim that they are capable of seeing and/ or experiencing strange visual hallucinatory episodes, consequently resulting in confabulation [1].

French writer Michel de Montaigne (1533-1592) first described this syndrome. In late 1890s Gabriel Anton (1858-1933), Austrian neuro-psychiatrist noted three patients, one with cortical blindness, one with deafness, and one with left sided hemiparesis all lacking self-perception of their deficit. Joseph Babinski (1857-1932), French neurologist in 1914 used the term 'Anosognosia' to describe hemiplegic patients with unawareness of their blindness [1,3].

Patients with Anton syndrome often find excuses for their symptoms such as there is not enough light to see or they may also put themselves in danger to prove their intact vision [4]. These patients act as though they could see, and in attempting to walk,

collide with objects, even to the point of injury. They may offer excuses for the difficulties—"I lost my glasses," "The light is dim"—or may only evince indifference to loss of sight. The lesions in cases of negation of blindness extend beyond the striate cortex to involve the visual association areas ^[5].

There are diverse causes of Anton syndrome, most common being bilateral occipital lobe infarction of posterior cerebral artery ^[6]. Other cause being obstetric complication such as pre-eclampsia and haemorrhage resulting in hypo-perfusion ^[7], Hypertensive encephalopathy ^[8], MELAS (Mitochondrial myopathy, Encephalomyopathy, Lactic Acidosis and Stroke like episodes) ^[9] Adrenoleukodystrophy ^[10], cardiac surgery ^[11], head trauma ^[12], Angiitis (autoimmune) of central nervous system ^[13]. Angiographic procedures, which disrupt blood brain barrier, coexisting with hypotension, embolism, and vasospasm can also cause cortical blindness ^[14]. Any condition resulting in systemic hypoxia mainly affects occipital cortex because it lies distal from central cerebral vasculature ^[15].

Why only some patients with cortical blindness, end up having Anton Babinski syndrome, is still unknown. However, there are various hypotheses postulated, one stating that along with primary visual cortex (brodmann area 17), visual association cortex (brodmann area 18, 19) is also compromised. The damage of visual association area, results in disconnection with speech and language area ^[16], ^[17]. Thus, functional speech area confabulates due to missing visual input. Dr G Goldenberg and colleagues explained this in 1995. Other hypothesis states this syndrome as hallucinatory sensation.

It is diagnosed by excluding anterior visual pathway disease by proper history taking along with complete neuro- ophthalmological examination. There are five criteria for clinical diagnosis of cortical blindness: a) loss of blink reflex in response to threat, b) loss of all visual impulse including light and dark, c) preserved light and accommodation- pupillary reflex, d) normal fundoscopic examination, e) preserved extra- ocular movements ^[4]. Once clinically diagnosed laboratory and radiological investigations are carried out to confirm the etiology of cortical blindness.

In this patient Computed tomography of brain revealed bilateral occipital fresh intracerebral haematoma. MRA was done further, which showed right parieto-occipital and small left occipital acute to sub-acute haematoma. Multiple scattered cerebral, pontine, and cerebellar petechial haemorrhage was observed.

The outcome of cortical blindness solely depends on the age of patient, etiology, severity, duration, initial recovery time, medical history. This patient was managed conservatively by lowering down blood pressure. Medicines used to lower blood pressure were amlodipine, perindopril, and mannitol.

Conclusion

Anton Babinski syndrome should always be suspected in-patient with evident occipital lobe damage presenting with denial of their blindness. Emphasis should be made on secondary prevention and rehabilitation of this syndrome. Absence of focal neurological deficits combined with denial of blindness makes the diagnosis-challenging like mentioned in the case report.

References

1. Zukic S, Sinanovic O, Zonic L, Hodzic R, Mujagic S, Smajlovic E. Anton's Syndrome due to Bilateral Ischemic Occipital Lobe Strokes. *Case Rep Neurol Med* 2014; 2014:474952.
2. Davis GP, Sewell RA, Levy B, Price BH, Cunningham MG. An atypical presentation of Anton syndrome in a patient with preserved cognition despite multiple cerebral infarcts: a case report. *CNS Spectr* 2009; 14(1):15-8.
3. Maddula M, Lutton S, Keegan B. Anton's syndrome due to cerebrovascular disease: a case report. *J Med Case Rep* 2009; 3:9028.
4. Yew KK, Halim SA, Liza-Sharmini AT, Tharakan J. Recurrent Bilateral Occipital Infarct with Cortical Blindness and Anton Syndrome. *Case Rep Ophthalmol Med* 2014; 2014:795837.
5. Ropper AH, Samuels MA, Klein JP. Neurologic Disorders Caused by Lesions in Specific Parts of the Cerebrum. In: Adams & Victor's Principles of Neurology. McGraw-Hill Inc. 10th edition. (Retrieved June 28, 2015 from <http://>

- accessmedicine.mhmedical.com/content.aspx?bookid=690&Sectionid=50910870)
6. Carvajal JJR, Cárdenas AAA, Pazmiño GZ, Herrera PA. Visual anosognosia (Anton-Babinski Syndrome): report of two cases associated with ischemic cerebrovascular disease. *J Behav Brain Sci* 2012; 2:394–8.
 7. Misra M, Rath S, Mohanty AB. Anton syndrome and cortical blindness due to bilateral occipital infarction. *Indian J Ophthalmol* 1989; 37(4):196.
 8. Nguyen-Lam J, Kiernan MC. Acute cortical blindness due to posterior reversible encephalopathy. *J Clin Neurosci* 2008; 15(10):1182-5.
 9. Alemdar M, Iseri P, Selekler M, Budak F, Demirci A, Komsuoglu SS. MELAS presented with status epilepticus and Anton-Babinski syndrome; value of ADC mapping in MELAS. *J Neuropsychiatry Clin Neurosci* 2007; 19(4):482-3.
 10. Trifiletti RR, Syed EH, Hayes-Rosen C, Parano E, Pavone P. Anton-Babinski syndrome in a child with early-stage adrenoleukodystrophy. *Eur J Neurol* 2007; 14(2):e11-2.
 11. Aldrich MS, Alessi AG, Beck RW, Gilman S. Cortical blindness: etiology, diagnosis, and prognosis. *Ann Neurol* 1987; 21(2):149-58.
 12. McDaniel KD, McDaniel LD. Anton's syndrome in a patient with posttraumatic optic neuropathy and bifrontal contusions. *Arch Neurol* 1991; 48(1):101-5.
 13. Amagasaki K, Takeuchi N, Kakizawa T, Shimizu T. Bilateral cortical blindness associated with cerebral angiitis. *Acta Neurochir (Wien)* 2002; 144(7):749.
 14. Alp BN, Bozbuğa N, Tuncer MA, Yakut C. Transient cortical blindness after coronary angiography. *J Int Med Res* 2009; 37(4):1246-51.
 15. Stiller RJ, Leone-Tomaschoff S, Cuteri J, Beck L. Postpartum pulmonary embolus as an unusual cause of cortical blindness. *Am J Obstet Gynecol* 1990; 162(3):696-7.
 16. Bartolomeo P. Visual neglect. *Curr Opin Neurol* 2007; 20(4):381-6.
 17. Santos CO, Caeiro L, Ferro JM, Albuquerque R, and Figueira ML. Denial in the first days of acute stroke. *J Neurol* 2006; 253(8):1016-23